JACS
Journal of Acute Care Surgery

Journal homepage: https:// www.jacs.or.kr
https://doi.org/10.17479/jacs.2022.12.2.82
eISSN : 2288-9582 pISSN : 2288-5862

Case Report

COVID-19 in a Patient Previously Exposed to Toxic Disinfectant from a Humidifier

Seok Hwa Youn, Sung Soo Hong, Sun Young Baek, Younghwan Kim *

Department of Surgery, National Trauma Center, National Medical Center, Seoul, Korea

Article history:
Received: March 3, 2022
Revised: May 21, 2022
Accepted: May 23, 2022

Corresponding Author:
Younghwan Kim
Department of Surgery, National Trauma Center, National Medical Center, 245, Eulji-ro, Jung-gu 04564, Seoul, Korea
E-mail: galgunbam2@daum.net

ORCID
Seok Hwa Youn
https://orcid.org/0000-0001-5983-3056
Sun Young Baek
https://orcid.org/0000-0002-3327-5938
Sung Soo Hong
https://orcid.org/0000-0001-7343-6276
Younghwan Kim
https://orcid.org/0000-0003-3836-8743

ABSTRACT

In August, 2011, the Korean Public Health Surveillance declared an outbreak of pulmonary disease due to the inhalation of humidifier disinfectants (HDs), which led to approximately 20,000 deaths. In March, 2020, the World Health Organization declared coronavirus disease-2019 (COVID-19) a pandemic. In this Case Report, we present a rare case of a patient who inhaled toxic HDs and developed COVID-19. He was young and had a low risk of severe COVID-19, however, he had a critical course to recovery. He was admitted to the intensive care unit and administered high-flow oxygen via a nasal cannula. He received dexamethasone injections each day for 10 days and his condition began to improve on hospital Day 6, although radiographical findings revealed no improvement. He was discharged on hospital Day 26. Despite the patient's chronic lung disease becoming asymptomatic, HDs could be an important risk factor affecting the clinical course of COVID-19.

Keywords: COVID-19, disinfectant, humidifier, lung diseases, risk factors

Introduction

In the Republic of Korea, an outbreak of pulmonary disease was declared on August 31, 2011, by the Public Health Surveillance [1]. The pulmonary disease was caused by the inhalation of humidifier disinfectants (HDs) which were sold between 1998 and 2011. There were more than 950,000 victims, with an estimated 20,000 deaths [1].

An outbreak of a respiratory disease caused by severe acute respiratory syndrome coronavirus-2 (coronavirus disease-2019 [COVID-19]) led to a pandemic being declared on March 11, 2020, by the World Health Organization. Initial chest computed tomography (CT) scan results of COVID-19 patients who are admitted, present as bilateral, multilobar ground-glass opacity (GGO) with peripheral or posterior distribution (or both) mainly in the lower lobes [2]. The overall probability of progression to critical disease is reportedly 5% which is defined as respiratory failure, septic shock and/or multiple organ dysfunction, and/or ICU admission [3]. However, critical disease differs according to age and its severity and mortality tend to increase with advanced age [3,4]. In addition to age, other risk factors can worsen the disease, one of which is chronic lung disease (CLD) [5,6].

There are very few reports of individuals who have experienced both pulmonary disease caused by the inhalation of HDs and COVID-19. We report a case of a patient who was 45-years-old, and was young enough to have a low incidence of critical disease, but whose condition critically deteriorated due to pulmonary disease caused by inhalation of HDs, which affected the course of COVID-19. This Case Report was approved by the Institutional Review Board (no.: NMC-2021-04-041), and informed consent was obtained from the patient.

Case Report

A 45-year-old Korean man, who was working as a Ukrainian dispatch, experienced symptoms of fever and dyspnea 2 weeks

prior to admission. As the patient's symptoms worsened, a real-time polymerase chain reaction for COVID-19 was performed, which yielded a positive result 2 days before admission. The patient was transported back to Korea on a private plane owned by the company that he worked for. At the airport, the patient was directly transferred to the ambulance and moved to an isolated intensive care unit for infection at the hospital. During the transfer, 7 L/min of oxygen was administered through a nasal cannula. The patient showed a poor general appearance and had severe dyspnea.

The patient had HD-associated lung injury (HDALI) which had caused fibrosis for 10 years and was treated regularly in the Department of Respiratory Medicine before becoming infected with COVID-19. He had a 20-pack-year smoking history which ceased at the time of diagnosis of lung injury. There was no other disease history that the Centers for Disease Control and Prevention suggested was associated with disease progression [6]. His symptoms of HDALI eventually improved, his radiology results were practically clear, and he did not experience difficulties in performing daily living activities.

Upon arrival, his blood pressure, pulse rate, and arterial oxygen saturation were 122/59 mmHg, 84/min, and 78%, respectively. High-flow nasal cannula (HFNC) oxygen therapy was administered at a flow rate of 60 L/min, a fraction of inspired oxygen (FiO_2) of 1.0, and an oxygen flow rate of 15 L/min were simultaneously delivered via a non-rebreather mask because the patient was mouth breathing due to severe dyspnea. After applying oxygen, arterial blood gas analysis (ABGA) was performed and results for the partial pressure of carbon dioxide (pCO_2) was 38.8 mmHg, partial pressure of oxygen (pO_2) was 67.6 mmHg, and arterial oxygen saturation (SaO_2) was 93.2%. Results of the initial laboratory tests were hemoglobin 14.3 g/dL, white blood cells 13,300/μL, platelets 563,000/μL, lactate dehydrogenase 480 U/L, γ-glutamyl transpeptidase 144 U/L, C-reactive protein 48.5 mg/L, aspartate transaminase 41 U/L, alanine aminotransferase 175 U/L, and creatinine 0.6 mg/dL. Procalcitonin rose to 0.05 ng/mL and myoglobin 115.7 ng/mL, while creatine kinase muscle brain and troponin 1 were 0.8 and < 0.10 ng/mL, respectively, and within normal range.

In 2015, CT was performed because the patient experienced severe symptoms of HDALI and showed multifocal GGOs with bubble-like lucency and air cysts in both lungs. In 2018, when the patient's symptoms and radiographical findings showed improvement, a repeat CT scan was performed and showed decreased multifocal patchy GGOs in both lungs (Figure 1).

Initial chest radiography performed after admission for COVID-19 treatment showed infiltrations in both lungs, and further radiographical findings revealed no improvement after 10 days. Twenty-six days after admission just prior to hospital discharge, chest radiography showed improvement in the patient's lung condition (Figure 2).

Dexamethasone (6 mg) was injected intravenously once a day for 10 days and eventually reduced to 3 mg intravenously once daily. Afterwards, the treatment was switched to oral methylprednisolone, administered at a dose of 6 mg. During the hospitalization period, no other medications, other than dexamethasone, were used for the treatment of COVID-19.

The patient remained on HFNC oxygen therapy with a non-rebreather mask while in the ICU and on Day 3, ABGA results were pCO_2 41.8 mmHg, pO_2 68.3 mmHg, and SaO_2 93.5% which were obtained whilst on HFNC oxygen therapy. On Day 6 of hospitalization, the patient was transferred to the isolation ward. The ABGA results were pCO_2 41.2 mmHg, pO_2 107 mmHg, and SaO_2 97.9%, and the HFNC oxygen flow rate was reduced to 30 L/min, the FiO_2 was decreased to 0.4, and the oxygen flow rate delivered via a non-rebreather mask was maintained at 15 L/

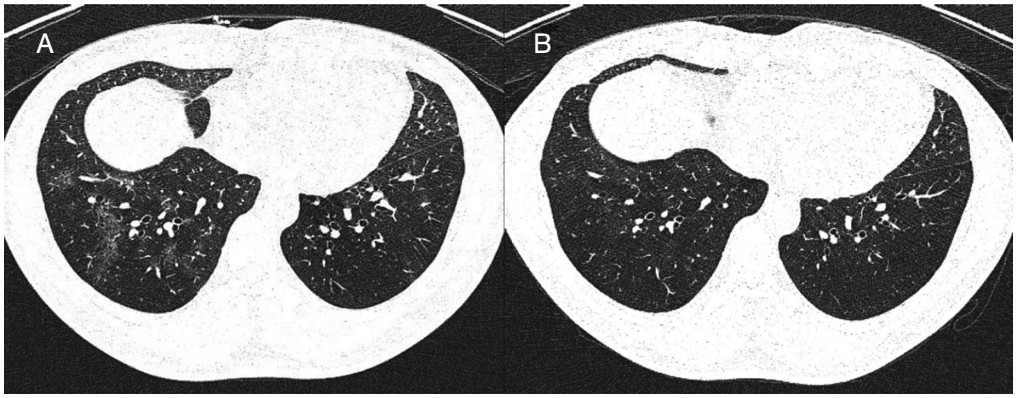

Figure 1. CT findings during a follow up for lung injury due to HDs inhalation. (A) Computed tomography, 6 years ago. Multiple focal GGOs with bubble-like lucency and air cyst in both lungs. Small nodules in the subpleural area of the right middle lobe and along the right major fissure Paraseptal emphysemas in the left upper lobe posterior segment; (B) Computed tomography, 3 years ago. Decreased extent of peribronchial multifocal patch GGOs in both lungs. Decrease in extent of focal reticulation. No change in the paraseptal emphysema in the LUL and small nodules in both lungs.
CT = computed tomography; HD = humidifier disinfectant; GGO = ground-glass opacity.

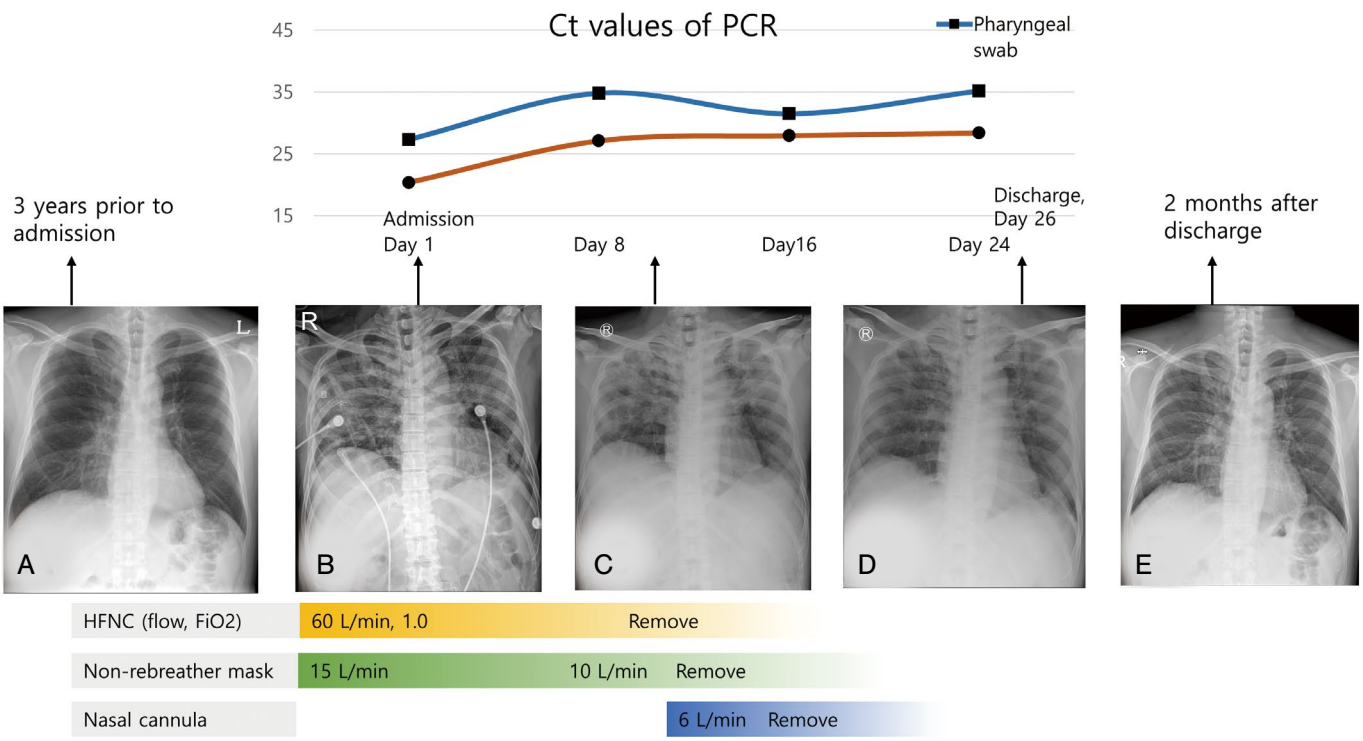

Figure 2. Cycle threshold values of PCR, oxygen treatments and chest X-ray findings according to hospital day. (A) 3 years prior to admission due to COVID-19 where there was an improved state of lung injury due to HDs inhalation; (B) Upon admission; (C) Hospital Day 11, HFNC was removed; (D) Hospital Day 26, prior to discharge; (E) Two months after discharge.
Ct = cycle threshold; HD = humidifier disinfectant; HFNC = high-flow nasal cannula; PCR = polymerase chain reaction.

min. A pulse oxygen saturation of 90% was maintained during meals, while only under HFNC oxygen therapy. The HFNC was removed on Day 11 of hospitalization, and the oxygen flow rate delivered via a non-rebreather mask, was reduced to 10 L/min. Meanwhile, chest radiography showed no improvement (Figure 2C). On Day 12 of hospitalization, 6 L/min of oxygen was delivered via a nasal prong instead of a non-rebreather mask. On Day 17 of hospitalization, oxygen therapy was only administered as necessary. Oxygen therapy was discontinued on Day 13 of hospitalization, and the patient was discharged on hospital Day 26; the PCR result for SARS-CoV-2 was positive (Table 1). Two months after discharge, the patient returned to the outpatient department for a follow-up appointment where the patient reported improved performance of daily living activities, and improved chest radiography was observed (Figure 2).

Discussion

In 2011, an outbreak of lung disease (HDALI) caused by inhalation of HDs was declared in Korea [7]. During the period of release (1998-2011), several companies manufactured HDs that could be mixed with water to eliminate microorganisms inside humidifier machines. Individuals exposed to vapor from HDs containing polyhexamethylene guanidine phosphate developed lung injury [8]. In severe cases individuals who developed lung fibrosis, died or underwent lung transplantation [9].

COVID-19 is a respiratory disease that was initially identified in Wuhan, China, in December 2019. It has a wide spectrum of symptoms, from an asymptomatic course or mild flu-like symptoms to respiratory distress [10,11]. One study reported that the severity of COVID-19 increases with age [12]. Patients > 65 years had a higher risk of admission to an ICU and had a higher risk of mortality [odds ratio (OR): 3.15 (1.40-7.09), p = 0.007]. When analyzing severity of COVID-19 by age, patients 41-60 years showed an OR of 1.90 (0.69-5.25), while those > 60 years showed an OR of 4.04 (1.32-12.36) compared with patients 1-20 years. Thus, the results showed that as age increased, the disease severity also increased [12].

The Centers for Disease Control and Prevention have suggested that patients with certain risk factors are more prone to developing severe COVID-19. These include cancer, chronic kidney disease, chronic liver disease, CLD, dementia, diabetes mellitus, Down syndrome, heart conditions, human immunodeficiency virus infection, an immunocompromised state, mental health conditions, obesity, pregnancy, sickle cell disease, thalassemia, smoking, transplantation, cardiovascular

disease, substance use disorders, and tuberculosis. In particular, they suggested that CLD included moderate to severe asthma, bronchiectasis, bronchopulmonary dysplasia, chronic obstructive pulmonary disease, and damaged or scarred lung tissue such as interstitial lung disease, cystic fibrosis, pulmonary embolism, and pulmonary hypertension [6].

Zheng et al reported that patients with a CLD, such as pulmonary fibrosis which is one of the main processes of HDALI, had a higher risk (OR: 5.15) of developing a critical condition [4]. However, studies on the CLD's role of progression are seldom reported [5].

In this current case, the patient was exposed to HDs, and pulmonary fibrosis progressed with dyspnea, which led to repeated hospital admissions. The most recent CT was performed 13 months prior to admission due to COVID-19 and showed a reduction in lesion size. Moreover, the patient showed improvements in the performance of daily living activities, and improvements were observed upon radiological examination. Hence, he was able to resume his business trip to Ukraine. The patient was in his mid-40s and had no risk factors for developing the severe COVID-19 other than a previous history of smoking and pulmonary fibrosis due to inhalation of HDs. Unfortunately, the patient's condition rapidly deteriorated even though there were few lung scars. He was admitted to the ICU and was intubated.

COVID-19 in patients exposed to toxic HDs are very rarely reported, so to generally apply the results of this single case to general cases should be taken with caution. Nonetheless, risk factors contribute to the progression of COVID-19 and may lead to critical disease. Despite the improvements in radiological findings and symptoms of CLD in this case such as HDALI with pulmonary fibrosis, determining CLD as a risk factor which may affect the clinical course of COVID-19 is important. Further studies about the impact of a medical history of lung disease on COVID-19 are needed to determine whether there is an association with critical progression of COVID-19.

Author Contributions

Study conception: YSH and HSS. Validation: YSH. Investigation: YSH. Manuscript writing: YSH and BSY. Manuscript review and editing: YSH and KY.

Conflicts of Interest

The authors have no potential conflicts of interest to disclose.

Funding

None.

Ethical Statement

Not applicable.

Data Availability

All relevant data are included in this manuscript.

References

[1] Byeon J, Kim H-S, Park M-Y, Lee K-M, Hong M-G, Choi Y-Y. An Estimation of Population at Risk of Exposure to Humidifier Disinfectant and Associated Health Effects. J Environ Health Sci 2020;46(4):457-69.
[2] Salehi S, Abedi A, Balakrishnan S, Gholamrezanezhad A. Coronavirus Disease 2019 (COVID-19): A Systematic Review of Imaging Findings in 919 Patients. AJR Am J Roentgenol 2020;215(1):87-93.
[3] Wu Z, McGoogan JM. Characteristics of and important lessons from the coronavirus disease 2019 (COVID-19) outbreak in China: Summary of a report of 72 314 cases from the Chinese Center for Disease Control and Prevention. JAMA 2020;323(13):1239-42.
[4] Zheng Z, Peng F, Xu B, Zhao J, Liu H, Peng J, et al. Risk factors of critical & mortal COVID-19 cases: A systematic literature review and meta-analysis. J Infect 2020;81(2):e16-25.
[5] Beltramo G, Cottenet J, Mariet A-S, Georges M, Piroth L, Tubert-Bitter P, et al. Chronic respiratory diseases are predictors of severe outcome in COVID-19 hospitalised patients: A nationwide study. Eur Respir J 2021;58(6):2004474.
[6] Centers for Disease Control and Prevention (US) [Internet]. People with certain medical conditions. [cited 2021 Dec 24]. Available from: https://www.cdc.gov/coronavirus/2019-ncov/need-extra-precautions/people-with-medical-conditions.html.
[7] Kim W-Y, Hong S-B. Humidifier disinfectant-associated lung injury: Six years after the tragic event. Tuberc Respir Dis 2017;80(4):351-7
[8] Park J-H, Kim HJ, Kwon G-Y, Gwack J, Park Y-J, Youn S-K, et al. Humidifier disinfectants are a cause of lung injury among adults in South Korea: A community-based case-control study. PLoS One 2016;11(3):e0151849.
[9] Hong S-B, Kim HJ, Huh JW, Do K-H, Jang SJ, Song JS, et al. A cluster of lung injury associated with home humidifier use: Clinical, radiological and pathological description of a new syndrome. Thorax 2014;69(8):694-702.
[10] John AE, Joseph C, Jenkins G, Tatler AL. COVID-19 and pulmonary fibrosis: A potential role for lung epithelial cells and fibroblasts. Immunol Rev 2021;302(1):228-40.
[11] Levin AT, Hanage WP, Owusu-Boaitey N, Cochran KB, Walsh SP, Meyerowitz-Katz G. Assessing the age specificity of infection fatality rates for COVID-19: Meta-analysis & public policy implications. Eur J Epidemiol 2020;35(12):1123-38.
[12] Khan A, Althunayyan S, Alsofayan Y, Alotaibi R, Mubarak A, Arafat M, et al. Risk factors associated with worse outcomes in COVID-19: A retrospective study in Saudi Arabia. East Mediterr Health J 2020;26(11):1371-80.